

Images in Endocrinology

Adrenal tuberculosis as a cause of Addison's disease

40 year old male presented with features of Addisonian Crisis. His serum cortisol was low (4.1 μ g/dl) with CT scan of adrenal glands showed bilateral enlargement. Histopathology of adrenals was suggestive of adrenal tuberculosis.

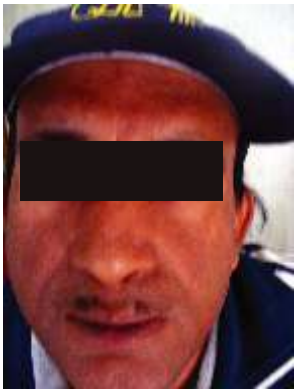

Fig. 1

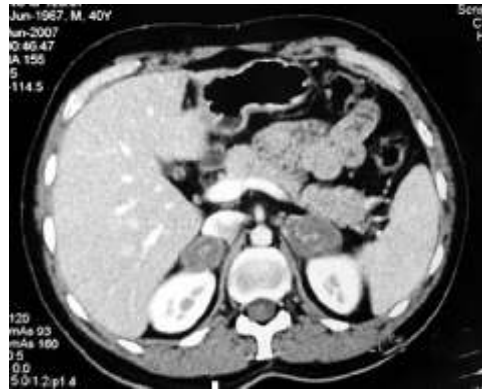

Fig. 2

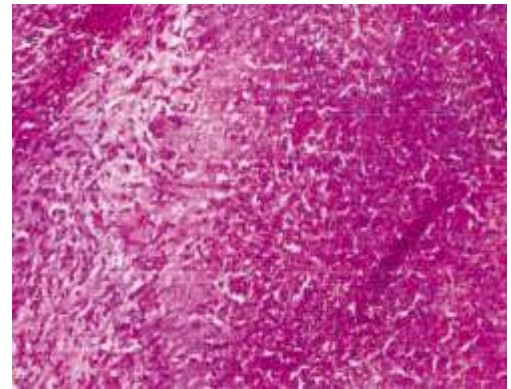


Fig. 3

Fig 1. Clinical photograph of the patient

Fig 2. NCCT of abdomen showing bilateral adrenal hyperplasia

Fig 3. Histopathological specimen of the patient showing caseating granulomas suggestive of adrenal tuberculosis.

BA Laway, Satish Koul, Hamdani Riyaz-u-Saif, Feroz Shaheen, Mohd Ashraf Ganie

Departments of Endocrinology* & Radiodiagnosis**,
Sher-i-Kashmir Institute of Medical Sciences, Srinagar, J&K.

E-mail : balaway@yahoo.com