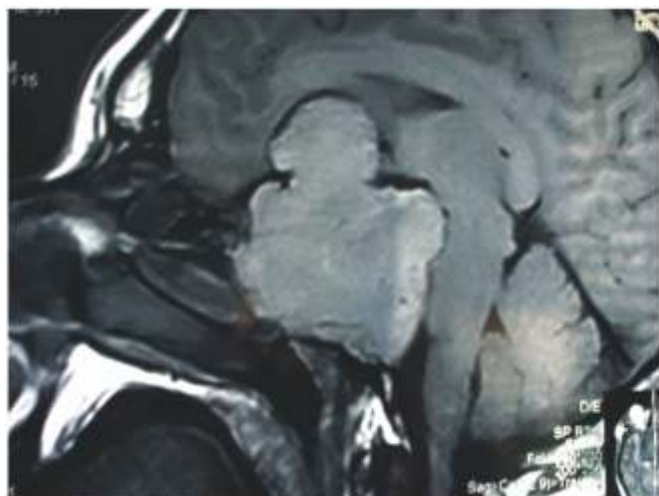
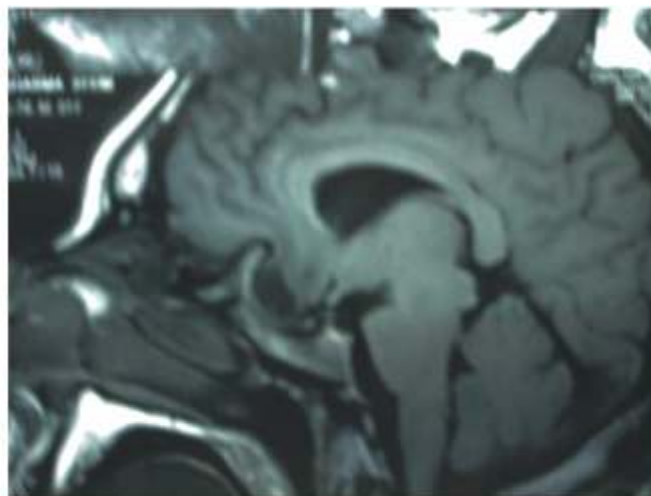


Images in Endocrinology

Benefit of Medical therapy in very large prolactinoma



A) Before Treatment



b) After treatment

Sagittal MRI of sella

A 27 years old recently married male presented as sexual dysfunction and headache. His prolactin was 257 ng/ml and MRI showed a huge pituitary tumour. In view of large tumour and compression of optic chiasma patient

was advised surgery by at least three neurosurgeons. He responded very well with tumour almost vanishing after 10 weeks of Cabergoline therapy.

Dinesh K. Dhanwal

Prof. of Medicine and Head of Endocrine Division
Maulana Azad Medical College, New Delhi
E-mail : dineshdhanwal@hotmail.com