

CASE REPORT

Mediastinal Parathyroid Adenoma- Detection by Technetium-99m MIBI Radionuclide Imaging.

Shoukat. H. Khan*, Tanveer A. Rather*, M. Ashraf Ganie**, Reyaz.A. Rangrez***

Departments of Nuclear Medicine*, Endocrinology**, Hospital Administration***, Sher-I-Kashmir Institute of Medical Sciences, Department of Radiology Srinagar, JK, 190011.

ABSTRACT

A thirty five year old male presented with fracture of the left femur .On evaluation he had elevated serum calcium .Subsequently his serum paratharmone was found to be elevated.USG revealed right kidney stones. Dual phase Technetium-99m MIBI scanning revealed an abnormal tracer concentration in chest suggestive of ectopic mediastinal parathyroid adenoma. We conclude that dual phase Technetium -99m MIBI imaging is a useful noninvasive technique for localization of parathyroid adenomas at normal and ectopic sites.[IJEM 2008;12(5):27-28]

Key Words: Parathyroid Adenoma, Ectopic, Mediastinum, Technetium-99m MIBI

INTRODUCTION

Preoperative localization of parathyroid adenoma not only reduces the operation time but also provides the operating surgeon a choice to undertake limited procedures like unilateral neck dissection or keyhole/endoscopic surgery thereby reducing the morbidity and mortality associated with extensive procedures. Preoperative localization is extremely useful in patients undergoing re-exploration for failed initial parathyroid surgery or persistent hypercalcemia. A variety of imaging techniques have been developed to accurately localize the abnormal glands prior to surgery that include both invasive and noninvasive modalities. Among the noninvasive techniques Technetium-99m MIBI scanning is used to localize the parathyroid adenomas both in neck as well as at ectopic sites with a sensitivity and specificity of 90% and 98% respectively(1).

Case History

A thirty five years old male presented to his doctor with a history of dull pain in the region of left knee joint. While he was under evaluation for this symptom, he sustained a trivial fall (from bed of 2 feet height) and sustained a fracture of his

left femur. He was subsequently evaluated and found to have a serum calcium of 14.68mg/dl, serum phosphorus of 4.0 mg/dl and serum alkaline phosphates of 2700 KA units. His serum paratharmone levels were 1445 pg/ml. His abdominal ultrasonography revealed right kidney stones. X-Rays of hands revealed periosteal resorption. Subsequently the patient was referred for Technetium-99m 7-methoxyisobutylisonitrile (Tc-99m MIBI) parathyroid imaging. The patient was injected 20 millicuries of Tc-99m MIBI intravenously and imaged for 5 minutes at 15 and 90 minutes post injection under a large field of view gamma camera (Siemens Orbitor) fitted with low energy all purpose parallel hole collimator. The 90 minutes image revealed an abnormal tracer concentration in the medias-tinum (Figure 1) suggestive of an ectopic para-thyroid adenoma. A follow up cont-rast enhanced CT (Figure 2) scan confirmed an anterior mediastinal mass lesion. The patient was operated and the mass removed was confirmed to be a parathyroid adenoma on histopathological examination.

DISCUSSION

Almost 83 % of the individuals have 4 parathyroid glands; 2 superior and 2 inferior glands. Approximately 13 % of the individuals have more than 4 glands and 3 % have less than 4 glands (2). Up to 20 % of the parathyroid glands can be ectopic and majority of them are located in the mediastinum (2).Persistent hyperparathyroidism after initial surgery may be due to incomplete excision of the parathyroid gland or it

For Correspondence:

Dr. Shoukat H. Khan
Head, Department of Nuclear Medicine, SKIMS, Srinagar, J &K,
190011. E-mail: drshkhan199@yahoo.co.in; Ph: 9419074250;
Fax: 0194-2403470

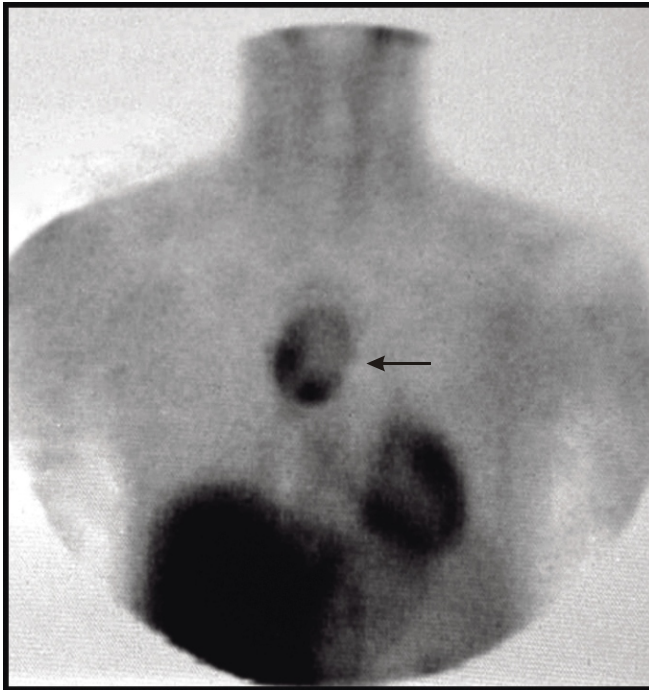


Figure 1: Technetium-99m MIBI image showing Ectopic (Mediastinal) Adenoma.

may be due to presence of ectopic or supernumerary glands which may be missed on initial evaluation and localization studies.

This case illustrates the usefulness of Tc-99 m MIBI in the localization of mediastinal adenomas and emphasizes the fact that a comprehensive imaging should include views of chest (mediastinum) as well as neck because of significant incidence of ectopic parathyroid tissue (3). Accumulation and retention of Tc-99-m MIBI is proportional to the blood flow and mitochondrial content of the tissue (4). It has been reported in the literature that parathyroid adenomas are mitochondria rich and that Tc-99-m MIBI is taken up avidly and released more slowly by these adenomas than the surrounding thyroid tissues (5). Early and delayed images with Tc-99-m MIBI take advantage of its differential kinetics. This differential washout time results in 90% sensitivity for

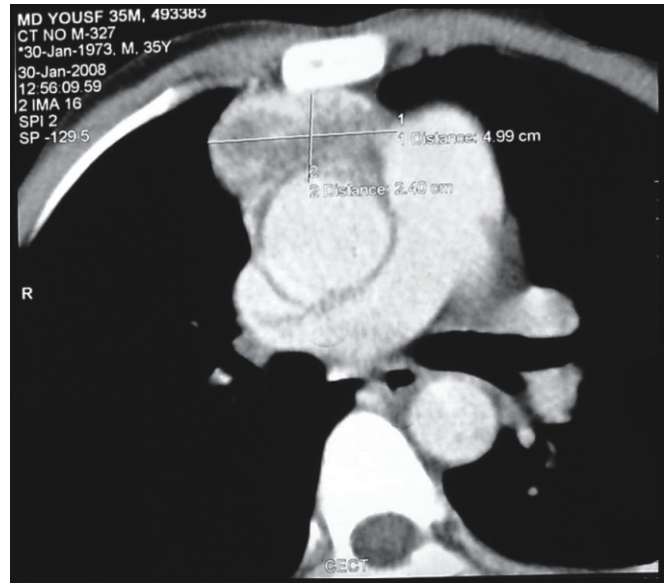


Figure 2: CAT scan Chest showing Ectopic (Mediastinal) Adenoma.

Tc-99m MIBI dual phase imaging for detecting parathyroid adenomas (6).

REFERENCES

1. Denham DW, Norman J. Cost effectiveness of the preoperative sestamibi scans for primary hyperparathyroidism is solely upon the surgeon's choice of operative procedure. *Am Coll Surg* 1998;186:293-304
2. Akerstorm G, Malmacus J, Bergstorm R. Surgical anatomy of human parathyroid glands. *Surgery* 1984; 95:14-21.
3. Rantis PC Jr, Prinz RA, Wagner RH. Neck radionuclide scanning: a pitfall in parathyroid localization. *Am Surg* 1995; 61:641-645.
4. O'Doherty MJ, Kettle AG, Wells P, Collins EC, Coakely AJ. Parathyroid imaging with technetium-99m sestamibi: preoperative localization and tissue uptake. *Nuclear Med* 1992;33:313-318.
5. Sandrock D, Merino MJ, Norton JA, Neuman RD. Parathyroid imaging by Tc/TI scintigraphy. *Eur J Nuc Med* 1990;16: 607-613.
6. Taillefer R, Boucher Y, Potrin C, Lambert R. Detection and localization of parathyroid adenomas in patients with hyperparathyroidism using a single radionuclide imaging procedure with technetium-99m sestamibi (double phase study). *J Nucl Med* 1992;33:1801-1807.